

## CASE REPORT

# Promontory fistula: A rare entity to see in a three tiers health system

Akshay Saxena, Chander Mohan, Abhinav Srivastava, O. N. Sinha

Department of ENT, Rohilkhand Medical College and Hospital, Bareilly, Uttar Pradesh, India

### Corresponding Author:

Dr. Abhinav Srivastava, Department of ENT, Rohilkhand Medical College and Hospital, Bareilly - 243 006, Uttar Pradesh, India.  
Mobile: +91-9794956306.  
E-mail: drabhinavsrivastava7@gmail.com

Received: 21-09-2019

Accepted: 17-10-2019

**How to cite this article:** Saxena A, Mohan C, Srivastava A, Sinha ON. Promontory fistula: A rare entity to see in a three tiers health system. Int J Adv Integ Med Sci 2019;4(2):39-41.

**Source of Support:** Nil,

**Conflicts of Interest:** None declared.

## INTRODUCTION

Long-standing chronic otitis media (COM) with cholesteatoma is the cause of bony destruction over the labyrinth and is one of the disabling intratemporal complication of COM, as it causes vertigo as well as sensorineural hearing loss. The most common location being the lateral semicircular canal, promontory representing the basal turn of the cochlea is not a common site because first, this area is not involved in the accumulation of cholesteatoma matrix substances, second, it is one of the densest bone of the human body, and finally, pressure necrosis from overlying tissue in this area is not common.<sup>[1]</sup> In the present health set up consisting of the primary, secondary, and tertiary levels of facility with lots of awareness and faster means of

Long-standing chronic otitis media (COM) with cholesteatoma is the cause of bony destruction over the labyrinth and is one of the disabling intratemporal complications of COM. The lateral semicircular canal being the most common and very few cases reported for promontory fistula. We report a case of promontory fistula which is rare to see in modern practice. One must consider this rare intraoperative finding in any patient of COM with severe to profound sensorineural hearing loss.


**KEY WORDS:** Cholesteatoma, cochlear fistula, profound sensorineural hearing loss, promontory fistula

transportation, it is very rare to find the case of fistula over promontory. We report a rare case of fistula over promontory.

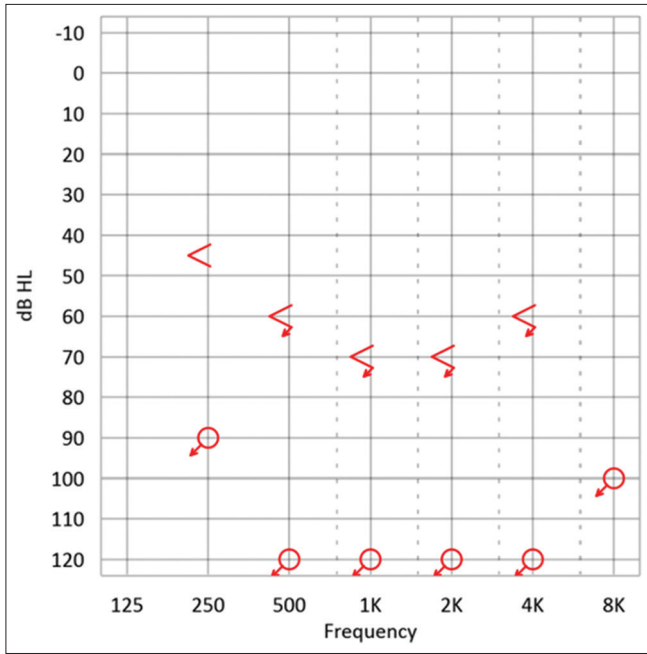
## CASE REPORT

A 50-year-old female presented in the department of otorhinolaryngology with complain of recurrent foul smelling discharge from the left ear for 30 years with decreased hearing from both ears. Her right ear got operated elsewhere 8 years back. There was no history of vertigo, facial asymmetry, but tinnitus was present, nystagmus was absent. She was diagnosed as a case of operated modified radical mastoidectomy right ear with the squamosal type of COM in the left ear. Pure-tone audiometry showed severe to profound hearing loss in both ears [Figures 1 and 2]. The patient was prepared for the left ear mastoid exploration under general anesthesia and fitness was obtained from anesthesiologist after required blood and X-ray investigations.

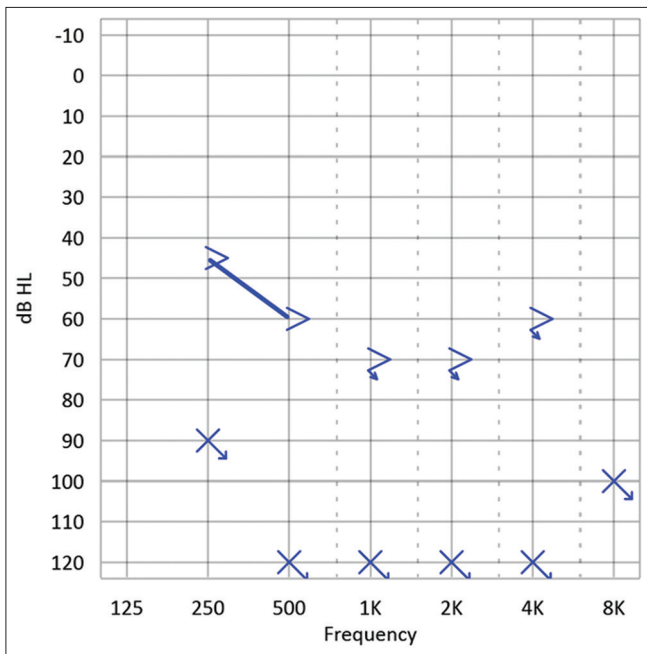
The patient was planned for canal wall down tympanomastoidectomy. During the surgery, it was found that cholesteatoma was a present and involved attic, mastoid antrum

Access this article online	
Website: <a href="http://www.ijaims.net">www.ijaims.net</a>	Quick Response code
	

This is an Open Access article distributed under the terms of the Creative Commons Attribution 4.0 International License (<http://creativecommons.org/licenses/by/4.0/>), allowing third parties to copy and redistribute the material in any medium or format and to remix, transform, and build upon the material for any purpose, even commercially, provided the original work is properly cited and states its license.



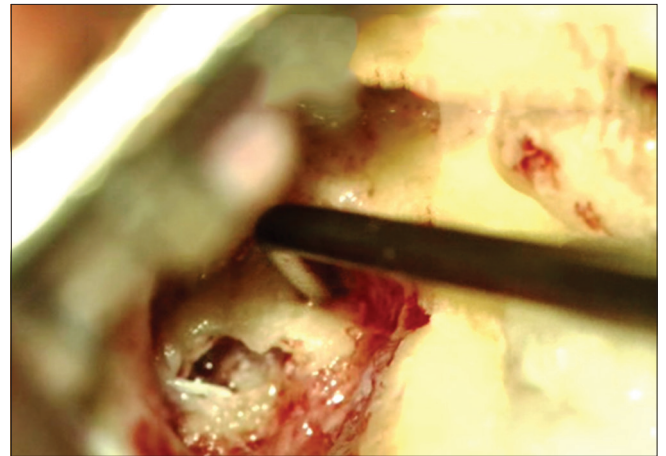
**Figure 1:** Pure-tone audiogram of the right ear showing profound mixed hearing loss



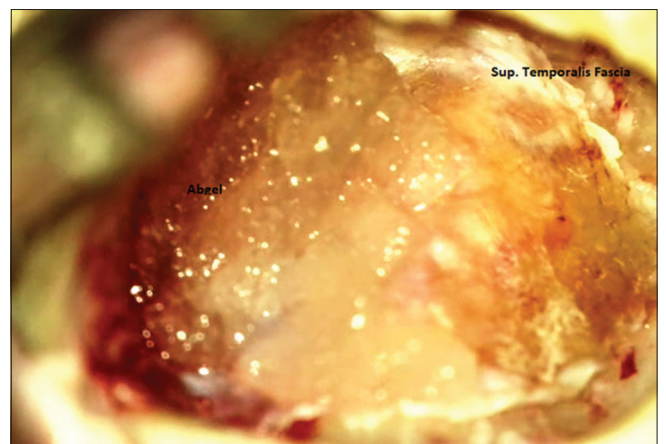
**Figure 2:** Pure-tone audiogram of left ear showing profound mixed hearing loss

extending to sinodural angle, tip cells, and sinus tympani. All ossicles were necrosed and absent, only mobile footplate was present. Granulation tissue was found over the region of the promontory; on decongesting and removing the granulation tissue over it, a fistula was present, which shows light reflex on moving stapes footplate [Figure 3].

Complete wall down was done, and disease was cleared from all parts of middle ear cleft. The fistula was closed with a piece of superficial temporalis fascia. Mastoid cavity so formed was



**Figure 3:** Positive light reflex on probing the bare oval window



**Figure 4:** Cavity packed with antibiotic soaked abgel

packed with antibiotic soaked Gelfoam after lining the cavity with superficial temporalis fascia [Figure 4].

Wide meatochoncoplasty was done, and the wound was closed in layers. In the post-operative period, the patient complained of vertigo and had nystagmus, which lasted for 5–6 days and resolved with supportive medications such as vestibular sedatives and antiemetics. The patient was discharged on the 7<sup>th</sup> day after stitch removal.

## DISCUSSION

Cochlear fistula in COM is one the rare entity with only few cases reported in the medical literature. Due to the very dense nature of the bone and not the common site of keratin accumulation, promontory becomes a very unusual site of fistula formation.

Sensorineural hearing loss in COM can be related to both chemical and mechanical irritations. Chemical damage is generally caused by penetration of noxious substances such as bacterial toxins into the labyrinth through the round window and fistula site. Endogenous toxins such as lipopolysaccharides, prostaglandins, and leukotrienes are possible chemical mediators for the causation and are usually present in middle

ear effusions.<sup>[2,3]</sup> Furthermore, when the cochlear endosteum is invaded by the cholesteatoma or was damaged during surgery, severe hearing loss occurs.<sup>[4]</sup>

The only treatment of such cases is a wall down mastoidectomy with meatochoplasty to make the ear safe for future. Intraoperative surgeon's needs to be cautious regarding meticulous dissection from membranous labyrinth so as to avoid further damage to the inner ear.

## CONCLUSION

Cochlear fistula in cases of chronic suppurative otitis media (COM) is one of the rare entity to be seen with documentation only in the literature. Although our health system has progressed

a lot, this possibility must be in mind if any patient presents with severe to profound hearing loss and prognosis should be explained in terms of poor hearing outcome.

## REFERENCES

1. Sakaida H, Takeuchi K. Cochlear fistula as a late consequence of tympanomastoidectomy. *Otol Neurotol* 2015;36:148-9.
2. Stenqvist M, Anniko M, Pettersson A. Effect of *Pseudomonas aeruginosa* exotoxin a on inner ear function. *Acta Otolaryngol* 1997;117:73-9.
3. Guo Y, Wu Y, Chen W, Lin J. Endotoxic damage to the stria vascularis: the pathogenesis of sensorineural hearing loss secondary to otitis media? *J Laryngol Otol* 1994;108:310-3.
4. Phelps PD. Preservation of hearing in the labyrinth invaded by cholesteatoma. *J Laryngol Otol* 1969;83:1111-4.